

erbe
power your performance.



ENDO CUT® I

Papillotomy procedures
with ENDO CUT® I

CONTENTS

INTRODUCTION	03
---------------------	-----------

TECHNOLOGY	04
ENDO CUT I	
Cutting cycle	
Coagulation cycle	
Equipment	
User interface	
Expert mode	
Activation and activation signals	

IN PRACTICE	07
General information	
General parameter settings	
Operative techniques	
Recommended Settings	

RECOMMENDED SETTINGS	12
-----------------------------	-----------

AVOIDING COMPLICATIONS	13
-------------------------------	-----------

LITERATURE	14
-------------------	-----------



Important information

While Erbe Elektromedizin GmbH has taken the greatest possible care in preparing this brochure and compiling the recommended settings, we cannot completely rule out errors. The information and data contained in the recommended settings cannot be used to justify any claims against Erbe Elektromedizin GmbH. In the event of compelling legal justification for a claim, liability shall be limited to intent and gross negligence.

Although the information on recommended settings, application sites, duration of application and the use of instruments is based on clinical experience, individual centers and physicians also favor settings other than those recommended here. This information is intended only as a guideline and must be evaluated by the surgeon for applicability. Depending on individual circumstances, it may be necessary to deviate from the information provided in this brochure.

Medicine is constantly subject to new developments based on research and clinical experience.

This is another reason why departing from the information provided here may be appropriate.



Over the past few years ENDO CUT has established itself as an accepted electrosurgical modality in endoscopic papillotomy procedures (EPT).*

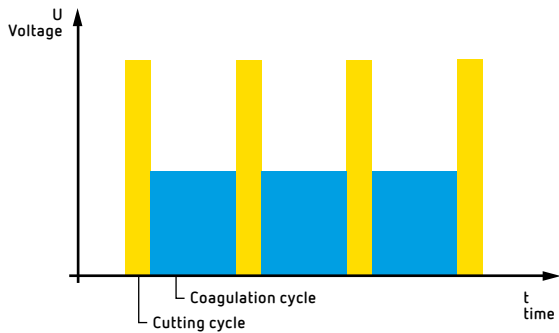
ENDO CUT I of the Erbe VIO System is a further development of the ENDO CUT offered by the "Erbotom ICC" series which was successfully used for more than 10 years. This brochure is intended to help users understand ENDO CUT I and to use it correctly in their clinical practice and provides information both for endoscopists and for the entire endoscopy team.

This brochure was created in close cooperation with experienced endoscopists working in different medical centers. Our particular thanks go to Prof. Schulz (Berlin), Dr. Maier (Püttlingen), and Prof. Riemann and Dr. Eickhoff (Ludwigshafen).

The recommended settings given in the insert included here were compiled by Erbe Elektromedizin and apply as of software version V 1.4.2.

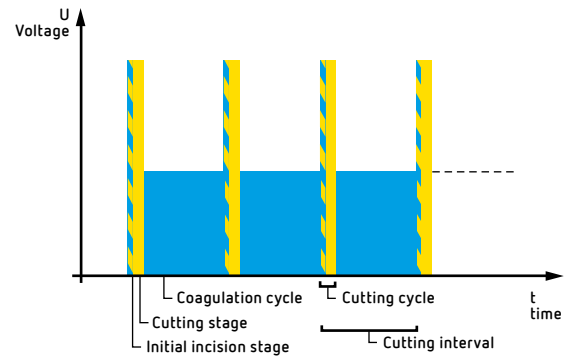
* In this brochure the term endoscopic papillotomy (EPT) is used synonymously for endoscopic sphincterotomy (ES or EST).

Technology



01

*Intermittent cutting mode ENDO CUT I:
cutting cycle (yellow), coagulation cycle (blue).*



02

*Cutting cycle with ENDO CUT I:
initial incision stage (yellow/blue), cutting stage (yellow)
and coagulation cycle (blue).*

ENDO CUT I

The fractionated cutting mode ENDO CUT I is characterized by alternating cutting and coagulation cycles (Fig. 1). This makes it possible to carry out controlled cutting with sufficient hemostasis during the entire cutting process, which supports the work of the operating physician.

In the more than 10 years in which ENDO CUT has been used in endoscopic procedures, experience has shown that voltage regulation and arcing recognition are the core features determining the quality and reproducibility of the cuts.

ENDO CUT I is a further development to ensure that papillotomy procedures are safe and effective. The safety switching device allows the papilla to be incised safely, irrespective of the electrical resistance of the tissue.

This reduces the danger of a delayed incision with its concomitant risk of unintended thermal injury in the area of the papilla.

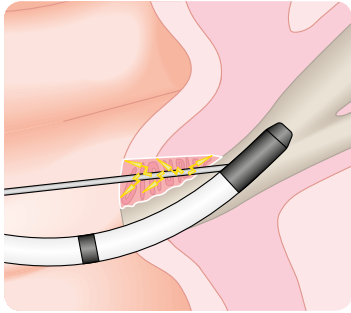
An abrupt, uncontrolled incision, the so-called "zipper effect", can possibly be avoided by using suitable settings.

ENDO CUT I is a monopolar high-frequency electrosurgical procedure, which consists of a two-stage cutting cycle followed by a coagulation cycle (Fig. 2):

Cutting cycle

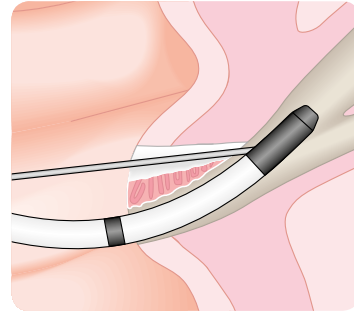
- a) initial incision stage
- b) cutting stage

Coagulation cycle



03

When cutting with a papillotome, small arcs (yellow) are created between the cutting wire of the papillotome and the tissue.



04

Coagulation during cutting. A coagulated area (gray/white) is created in the vicinity of the cutting wire.

CUTTING CYCLE

a) Initial incision stage

A cutting cycle always begins with a short initial incision stage of varying duration (Fig. 2). It serves to heat the tissue in the immediate vicinity of the cutting wire endogenously to 100° C (212° F) within a few tenths of a second, leading to a tiny initial coagulation (hemostasis) of the tissue just prior to the actual cutting stage.

b) Cutting stage

The beginning of the cutting stage is characterized by the development of electric arcs (sparks) between the tissue and the cutting wire of the papillotome (Fig. 3). The arcs have a voltage > 200 volts and are generated as soon as the vaporization of liquid in the tissue creates a small gap between the cutting wire and the tissue of the papilla.

To create controlled and reproducible cuts the formation of sparks must be detected automatically. This will ensure that the length and quality of the cut is reproducible.

In the cutting mode ENDO CUT I, the cutting stage is automatically regulated through the recognition of spark formation.

COAGULATION CYCLE

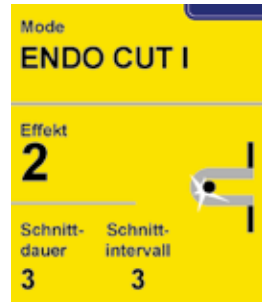The coagulation cycle prepares the tissue for the next cutting cycle to ensure various levels of hemostasis prior to any subsequent cut.

The **intensity** of the coagulation, the so-called coagulation **effect**, can be modified with ENDO CUT I using four different settings.

The **duration** of the coagulation cycle can be minutely adjusted using the Expert mode (see chapter "Cutting interval", page 8). It is important to remember that coagulation is significantly influenced by the Effect setting and less by the duration of the coagulation process.

Depending on the chosen setting, the coagulated area at the margins of the incision will increase (Fig. 4).

ENDO CUT I
in the Expert mode



07

User interface
of the VIO system



06

GI workstation VIO 200 D



05

Equipment

ENDO CUT I is a consequential further development of ENDO CUT, a well-known feature of the ICC units.

The Endo Cut IQ mode, an optional upgrade, is available for the electro-surgical VIO units, some of which can be retroactively equipped with the mode.

A complete system for endoscopic procedures could consist of the following (Fig. 5):

- VIO electro-surgical unit
- VIO electro-surgical unit Argon Plasma unit APC 2 and
- Endoscopy irrigation pump EIP 2
- Integrated on the VIO cart.

USER INTERFACE

ENDO CUT I is a cutting mode. This means that on the monitor or the user interface the ENDO CUT I is displayed in the yellow field (Fig. 6).

Normally only the parameter "Effect" is displayed. The Effect setting determines the intensity of coagulation during cutting.

EXPERT MODE

It is also possible to activate the Expert mode to carry out individual adjustments (Fig. 7). Once the Expert mode has been activated (this should only be carried out by the service technician), the parameters "Cutting duration" and "Cutting interval" will also be displayed on the monitor and can be individually adjusted.

ACTIVATION AND ACTIVATION SIGNALS

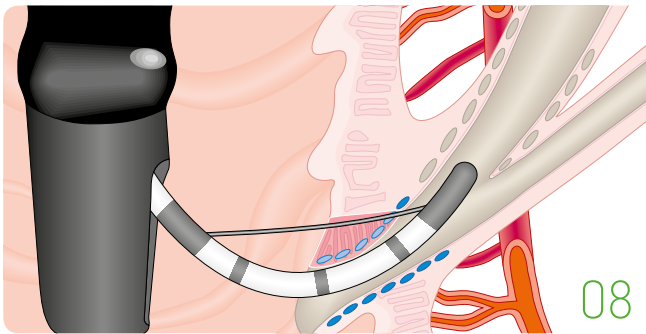
ENDO CUT I is activated by pressing the yellow foot pedal. The user is made aware of the activation by an acoustic signal, the activation signal.

As soon as cutting effectively begins, a second acoustic signal will be heard, the cutting signal. The cutting signal serves as an acoustic control for the actual cutting.

The yellow pedal of the foot switch should remain pressed down until the papilla has been sufficiently incised or there is a need to reposition the electrode or make other adjustments.

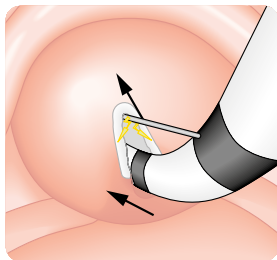
The cutting stage can be interrupted at any time by ceasing to activate the foot pedal.

In practice



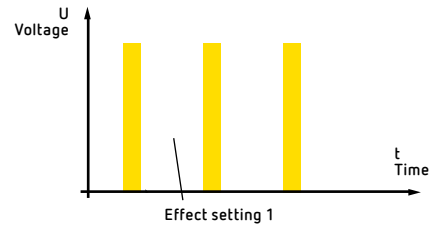
08

Anatomical view during a biliary papillotomy procedure: sphincter of Oddi (blue), sphincter muscle of the choledochal duct (gray), gastroduodenal artery and branching blood vessels (orange/red).



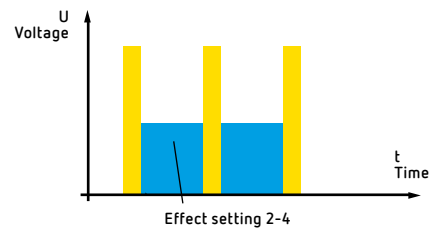
09

Direction of the incision in a biliary papillotomy procedure.



10

ENDO CUT I with Effect setting 1: cutting current (yellow) without coagulation.



11

With ENDO CUT I the coagulation effect (blue) can be increased using the effect levels 2 – 4

General information

Papillotomy procedures are performed to open up the bile duct or the pancreatic duct. Depending on the indication, this means that the sphincter of the papilla and the choledochal duct must be either partially or completely divided (s. Figs. 8/9). To minimize the dangers resulting from unintentional thermal damage (pancreatitis, perforation) many operating surgeons prefer to use only cutting current.

As in 30% of cases the superior pancreaticoduodenal artery (branch of the gastroduodenal artery) runs cranial to the choledochal duct, many operating surgeons recommend using a current with a higher capacity for coagulation for incisions which are close to the duodenal wall.

General parameter settings

EFFECT SETTINGS

Depending on the medical indications it will be necessary to use different coagulation effects to ensure that the papillotomy procedure is carried out with minimal blood loss and the least amount of collateral thermal damage. The intensity of the coagulation can be adjusted with the help of the parameter "Effect", using four different Effect settings.

Setting 1

With Setting 1 no coagulation is carried out between individual cutting cycles (Fig. 10). The current applied with this setting is a purely cutting current.

Setting 2

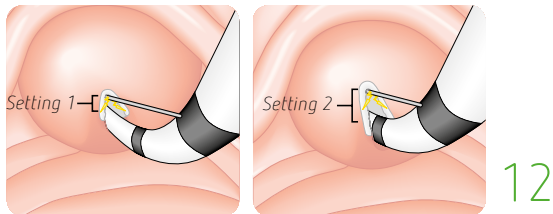
With Setting 2 a very slight coagulation occurs between the individual cutting cycles (Fig. 11).

Setting 3

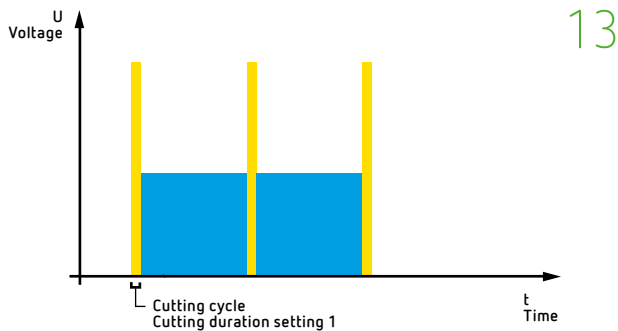
With Setting 3 the degree of coagulation between the individual cutting cycles is increased.

Setting 4

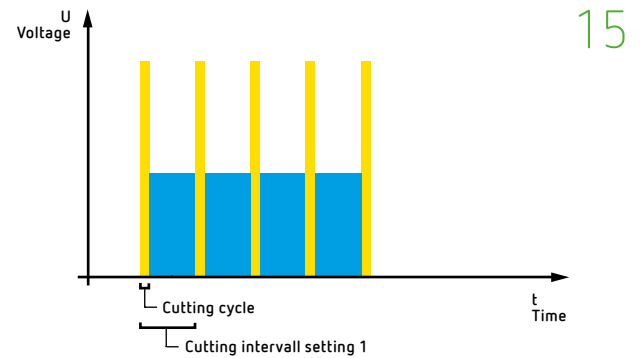
With Setting 4 the coagulation between the individual cutting cycles is maximized compared to Setting 3. This setting is particularly suitable for applications which require extensive coagulation.



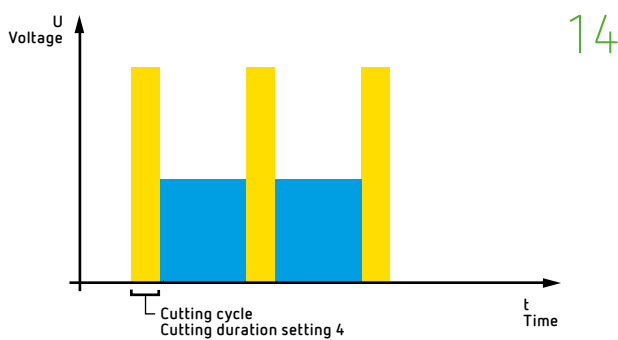
Cutting duration and extent of incision: left side = Setting 1, limited length of cut; right side = Setting 4, greater length of cut.



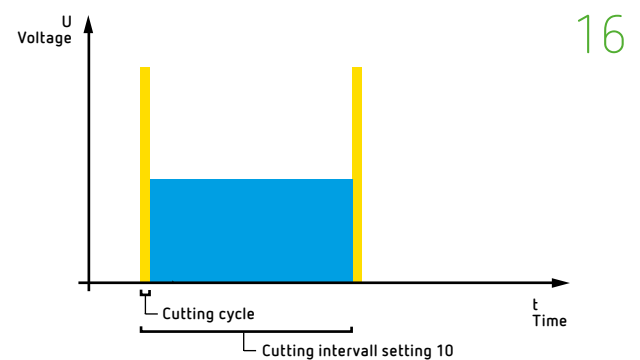
ENDO CUT I with a very short cutting duration: Setting 1.



ENDO CUT I with a cutting interval set to Setting 1: the coagulation cycle (blue) with the shortest possible cutting interval.



ENDO CUT I with the longest cutting duration: Setting 4.



ENDO CUT I with a cutting interval set to Setting 10: maximum duration of a coagulation cycle (blue) with the longest possible cutting interval.

CUTTING DURATION

The extent of the incision can be varied, depending on the individual requirements (Fig. 12). The length of the incision is significantly influenced by the cutting duration and can be adjusted using 4 different settings. If the cutting duration is short (careful, slow cut), more cutting cycles will be necessary than when using longer cutting times.

Setting 1

With Setting 1 the cutting duration is very brief, which limits the length of the cut (Fig. 13).

Settings 2 – 4

With Setting 2 the duration of the cut is somewhat longer resulting in a cut with a moderate length.

Settings 3 and 4 have a longer cutting duration, leading to longer cuts. We recommend using Setting 3 as the standard setting.

Setting 4 (Fig. 14) with the longest cutting cycle creates the longest cut, which is also a result of the rapid cutting.

CUTTING INTERVAL

A cutting interval consists of a cutting and a coagulation cycle (Fig. 15). It is defined as the period of time between the beginning of one cutting cycle and the beginning of the next.

Adjustments to the duration of the cutting interval serve to control the fractionated cut. A short cutting interval favors a more rapid cut, longer cutting intervals result in a slower and more controlled cut.

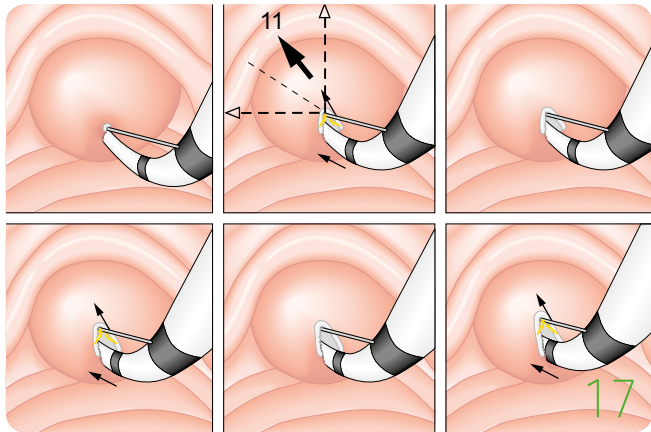
With the help of the parameter "Cutting interval" (in the Expert mode, see page 7), the duration of the coagulation cycle can be individually extended using 10 different settings. It should be noted that while the cutting interval will influence coagulation, the intensity of the coagulation is significantly influenced by the selected Effect setting (see page 7).

Settings 1 – 10

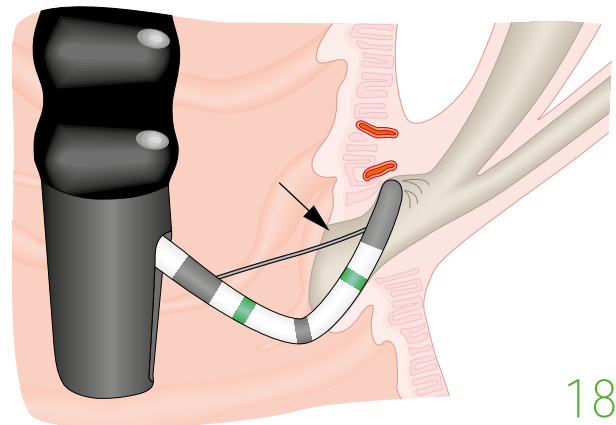
In Setting 1 there is only a very short break between the individual cutting impulses.

The higher the setting, the longer the cutting interval and the longer the coagulation cycle (Fig. 16).

Operative techniques



Introduction of the papillotome and direction of the cut in biliary papillotomy procedures. The markings at the distal tip of the papillotome indicate how deeply the papillotome is inserted. The arrows show the direction of the incision carried out to open up the papilla.



Papillotome which has been pulled too tight: there is no proper contact between the cutting wire of the papillotome and the tissue (s. arrow).

PROBING

15

To find the bile duct, the opening of the papilla must be examined carefully to discover where bile is secreted.

In cases where access is more difficult, the papillotome is placed at the opening of the papilla and the choledochal duct is identified after injection with contrast medium. Alternatively, papillotomes with guide wires are increasingly being used as they offer easier cannulation with better monitoring of the location. If probing and/or cannulation is still unsuccessful, it may be necessary for the operating physician to carry out a precut papillotomy (see page 11).

INSERTION

Where and how?

The insertion of a papillotome generally requires 4 consecutive steps:

1. The papillotome is tautened slightly, its distal tip is placed on the opening of the papilla and the papillotome is introduced using a slight counterclockwise rotation.
2. Using the Albarran lever, the papillotome is raised in the direction of the bile duct and the tip of the papillotome is used to push the roof of the papilla slightly upwards. The cutting wire should be positioned in the left upper quadrant in the direction of the choledochal duct, preferably in the 11 o'clock position (Fig. 17).
3. From the endoscopist's point of view the choledochal duct rises in a caudocranial direction ventrodorsally, so that the tip of the endoscope should then be bent upwards (large wheel).
4. In the final step the entire endoscope is slightly retracted. This will permit the wire to be positioned tangentially which is necessary for successful cannulation of the choledochal duct.

If it is not possible to introduce the papillotome by this means, a papillotome with a guide wire can be used, which may also be helpful in overcoming obstacles such as strictures, stones or tumors.

How deep should the insertion be?

When introducing the papillotome, it is important to take note of the markings. Only one third or maximally one half of the cutting wire should be inserted (Fig. 17). It is important to ensure that there is sufficient contact between the wire and the tissue of the papilla. If the papillotome is inserted too deeply for reasons of assumed safety, it will be more difficult to control the length of the incision. This will increase the danger of bleeding or perforation.

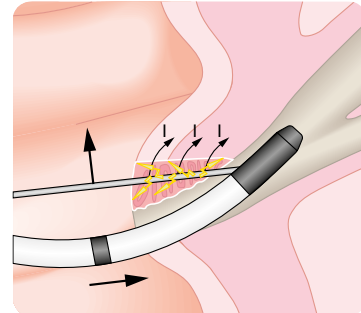
How much contact between wire and tissue?

The cutting wire of the papillotome must have sufficient contact to the tissue, as cutting is only possible when there is a sufficiently large contact area between the two. If the wire of a papillotome with a guide tip is tightened too much, there is a risk that the cutting wire will be pushed away from the tissue and there will no longer be a sufficiently large contact area with the tissue (Fig. 18).

How great should traction on the papillotome wire be?

The wire must not be too tight as otherwise the tip of the papillotome will be pressed into the tissue with a subsequent risk of mechanical perforation (Fig. 18).

Operative techniques



19

Direction of the incision in papillotomy procedures. The large black arrows indicate the direction of the incision when opening the papilla. The small arrows marked with an 'I' show the direction of the current flow during cutting.

ACTIVATION OF ENDO CUT I

a) Activation time

The yellow pedal of the foot switch is used to activate the cutting function of ENDO CUT I. The foot switch must remain pressed down continuously until the papilla has been sufficiently incised and opened.

In contrast to technologies without an ENDO CUT function, with ENDO CUT I the cut is no longer monitored by briefly pressing down the foot switch at intervals of 1 – 2 seconds. The fractionated cutting mode ENDO CUT I automatically ensures that cutting is slow and controlled, even though the foot switch remains continually activated; this reduces the risks associated with abrupt cutting.

b) Output setting

With ENDO CUT I the electrocautery output is automatically adjusted by means of the Effect settings, the cutting duration and the cutting interval. It is not necessary to adjust the power output (wattage) or to indicate the maximum power output. The electrocautery current is automatically adjusted and depends on the electrical resistance of the tissue. Please refer to the supplementary sheet enclosed (or see page 12) for information concerning recommended settings for different operative techniques.

CUTTING

The goal with every incision made using electrocautery current is to create a controlled, smooth cut with as much coagulation as necessary (hemostasis effect), preferably without carbonization and with only very little smoke plume. Cutting should be carried out cautiously in small steps (2 – 3 mm) to allow for constant visual monitoring between the individual cutting current impulses.

The fractionated cutting mode of ENDO CUT I was developed precisely for this purpose. The alternations between pure cutting and coagulation current make it easier to control the cutting process.

The desired cutting and coagulation effects can be separately and individually adapted to suit the requirements of the individual patient situation.

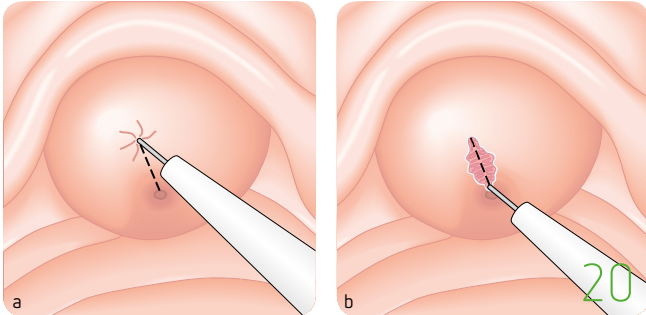
How extensive should the cut be?

The extent of the papillotomy will depend on the size of the papilla, the indication, and the width of the choledochal duct, which will become visible during the operation.


If a stent implantation is planned, the incision should be on the small side (≤ 1 cm, Soehendra et al., 2005) while for the extraction of stones the incision should be somewhat larger, depending on the size of the stone (> 1 cm, Soehendra et al., 2005). The first duodenal fold above the papilla serves as a rough cranial anatomic limitation. The direction of the incision is shown in Fig. 19.

PAPILLOTOMY PROCEDURES IN THE PANCREATIC DUCT

The procedure in papillotomies of the pancreatic duct is similar to that of papillotomies of the bile duct. In papillotomies of the pancreatic duct the incision should follow the course of the major pancreatic duct. The cut should be more horizontal and is carried out clockwise in the 1 o'clock direction. To avoid the risk of postoperative pancreatitis, coagulation should be kept as low as possible during cutting. With ENDO CUT I, no active coagulation occurs between the individual cutting cycles when the Effect setting is set to 1. A purely cutting current with minimal, immanent coagulation is created.



Needle-knife papillotomy. a) The needle-knife is placed on the papilla and a slight pressure is exerted. b) The papilla is gradually opened, layer by layer, along the dotted line using PreCut.



Different types of papillotomes: a) with a guide tip; b) without a guide tip; c) precut papillotome; d) flat needle papillotome; e) round needle papillotome.

PRECUT PROCEDURE

If selective cannulation of the bile or pancreatic is unsuccessful, it will sometimes be necessary to open the roof of the papilla in order to better identify the duct openings. This is also referred to as a precut papillotomy. For this procedure the precut papillotome is inserted into the opening of the papilla, the wire is aligned in the 11 or 12 o'clock position (bile duct) or in the 1 o'clock position (pancreatic duct), and the roof of the papilla is incised. After opening the papilla, the precut papillotome is exchanged for a standard papillotome.

If a needle-knife is used, it should be positioned slightly above the opening of the papilla and pressed lightly against the roof of the papilla. ENDO CUT I is activated, and the needle-knife is gradually guided upwards (Fig. 20) or downwards using a gentle see-saw movement. To avoid injuries the needle of the instrument should not be extended too much. The needle-knife is used to gradually open up the bile duct (layer by layer). Once the bile duct has been opened, bile will leak out.

A standard papillotome is then used to expand the opening.

Special precut papillotomes or needle-knives are used in papillotomy procedures.

SPECIAL FEATURES OF PAPILOTOMES

Figure 21 shows different papillotomes used in standard papillotomy procedures.

Papillotomes with a single monofilament wire are used for standard procedures, to carry out a quick incision with only a narrow margin of coagulated tissue.

In rare cases papillotomes with polyfilament wires are used, which result in a greater degree of coagulation along the margin of the incision compared to papillotomes with monofilament wire.

Papillotomes with guide wire

If the guide wire is left in place during a papillotomy procedure, then it is important to use only electrically insulated wire. In addition it is recommended to use a double or multilumen papillotome.

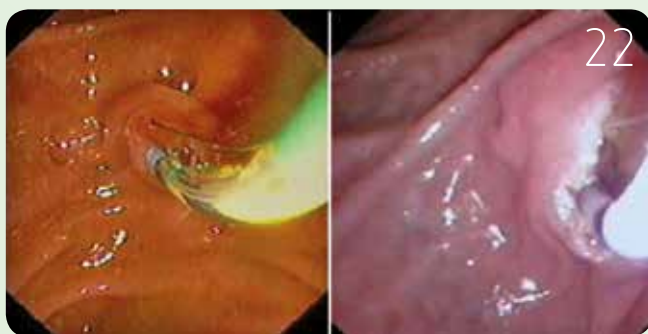
Precut papillotome

Compared to a standard papillotome, a precut papillotome has no guide tip and the cutting wire is slightly shorter and passes over the tip of the papillotome (Fig. 21c). This makes it easier to carry out the first incision.

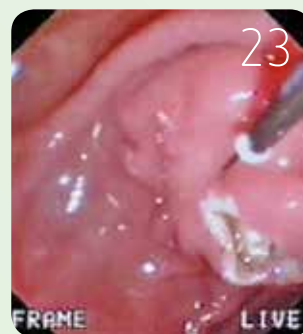
Precut needle-knife

Needle-knife papillotomes can be used for a precut papillotomy or to puncture (fistulotomy) or incise the roof of the papilla. Precut papillotomy procedures should only be carried out by an experienced physician using precut instruments, as the risk of perforation is higher!

Recommended settings for ENDO CUT[®] I



Papillotomy procedure with a standard papillotome:
a) inserted papillotome, b) opening up the papilla.



Precut papillotomy with a
needle-knife papillotome: opening
up the papilla.

Bile duct

Pancreatic duct

Papillotomies with a standard papillotome	ENDO CUT I	
	Bile duct	Pancreatic duct
Effect	Setting 2	Setting 1
Cutting duration	Setting 3	Setting 3
Cutting interval	Setting 3	Setting 3

Precut papillotomy using a pre-cut or a needle-knife papillotome	ENDO CUT I	
	Bile duct	Pancreatic duct
Effect	Setting 1	Setting 1
Cutting duration	Setting 3	Setting 3
Cutting interval	Setting 3	Setting 3

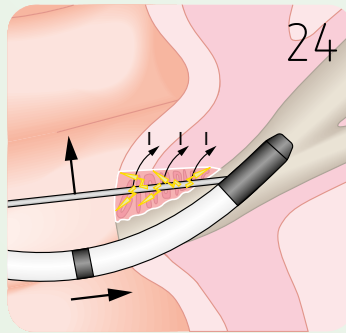
PRINCIPLE:

ENDO CUT I is characterized by an intermittent cutting current and a coagulation current; the duration and intensity of the current can be individually adjusted. Pure cutting current (for example pre-cut): a quicker, smoother cut but with a greater risk of bleeding

Pure coagulation current: a slow cut with a broader coagulation margin and greater degree of edema formation with a lower risk of bleeding but a higher potential risk of perforation and pancreatitis.

Available as of software version V 1.4.2

Avoiding complications



Hemostasis: the cutting wire of the papillotome is positioned as close to the source of bleeding as possible. The arrows indicated with an 'I' show the direction of the current flow.

The most common complications after an endoscopic papillotomy procedure are acute pancreatitis, bleeding, cholangitis, and perforations. Longer term complications include primarily recurrent pancreatitis and the formation of strictures.

The following chapter offers hints and pointers on how to use ENDO CUT I to avoid acute complications.

INTRAOPERATIVE BLEEDING (PRIMARY BLEEDING) DUE TO INSUFFICIENT THERMAL HEMOSTASIS

The occurrence of low level bleeding which resolves spontaneously during sphincterotomy is very common and is generally not considered a complication. The degree of hemostasis created during an electrosurgical incision is influenced by the choice of coagulation effect (Effect setting). Bleeding occurs more frequently with the ENDO CUT I at Effect setting 1 (which is defined as an effect without a coagulation cycle).

The first step towards avoiding heavy bleeding consists in having detailed anatomic knowledge, particularly of the arterial blood supply of the region around the papilla and the specific features of the individual patient. Heavy bleeding (which does not resolve spontaneously or is spurting) can be caused by a too long incision, an incision in the wrong direction, a zipper effect (e.g. intraoperative perforation) or vessel anomalies and requires intervention by the physician. Hemostasis is primarily carried out electrically using the papillotome: the blue foot switch is briefly activated in the mode FORCED COAG 60 Watts at Effect setting 2 (Fig. 22). However it is important to remember that if the activation is maintained for too long, this will result in deep trauma to the tissue. Other pharmacological and medical measures include subcutaneous injection (for example of an adrenalin solution) and the application of clips. When using clips it is important to avoid any injury to or occlusion of the pancreatic duct.

PANCREATITIS RESULTING FROM TOO EXTENSIVE COAGULATION

Too much coagulation increases the risk of undesirable thermal side-effects such as thermal injury to the pancreatic duct, which can subsequently lead to pancreatitis. To avoid this complication the coagulation effect can be reduced by one setting and the cutting duration increased by one setting (rapid cutting).

INTRAOPERATIVE PERFORATION WITH ELECTROSURGICAL CURRENT

Perforations are serious but rare complications which can occur in the course of a papillotomy procedure. They usually result from too wide incisions and/or uncontrolled cutting, which can be due to:

- ☑ too much traction of the wire
- ☑ too deep insertion of the papillotome
- ☑ too much mechanical pressure by the endoscope
- ☑ a choice of cutting interval which was too long
- ☑ continuous energy output for a too long period.

POOR CUTTING EFFECT

An inadequate cutting effect can be the result of too little contact between the wire of the papillotome and the tissue. This creates a high electrical transfer resistance which reduces cutting performance or even completely obliterates it.

CHECKLIST TO AVOID COMMON MISTAKES OCCURRING DURING PAPILOTOMY PROCEDURES

1. Is the papillotome positioned in the right direction?
2. Is cannulation simple?
 - a. Will it be necessary to use a guide wire?
 - b. Will it be necessary to carry out a precut papillotomy?
 - c. Precut: needle-knife or wire papillotomy?
3. Has the papillotome been inserted to the right depth?
4. Is the impulse directed in the right direction?
5. Is the tension on the wire properly adjusted?
6. Have the recommended settings been followed?
7. Activation of the yellow foot switch.
8. The foot switch should not be pressed several times consecutively!
 - a. Cutting speed?
 - b. Coagulation margin?
 - c. Sufficiently long incision?

BRIEF ACTIVATION OF THE FOOT SWITCH

In contrast to other cutting modes and to older technologies the ENDO CUT I mode does not require the foot switch to be pressed briefly to control the cut. Quite the contrary: the foot pedal should be pressed continuously throughout the procedure until the desired effect has been achieved.

If the foot pedal is pressed only briefly during resection, the coagulation effect is insufficient and the risk of bleeding increases when using effect level 2 and higher.

DEFECTIVE INSTRUMENTS/ACCESSORIES

Only connecting cables without any defects should be used. Loose connecting plugs can lead to the creation of arcs at the connecting parts which can negatively affect the control of the procedure. This might prematurely interrupt the cutting stage and prevent any further cutting.

With papillotomes it is important to ensure that the cutting wire can be easily opened and closed via the shaft. On no account may defective papillotomes be used.

FAULTY APPLICATION OF THE PATIENT PLATE

The area of contact between the patient plate and the skin must always be as large as possible. Any intraoperative lessening of the contact, for example if the patient plate comes off, can result in thermal damage to the skin. Improperly placed electrodes or reusable silicon patient plates with a higher impedance can negatively influence the effect of ENDO CUT I.

We generally recommend the use of disposable dispersive electrodes (NESSY patient plates) which will also ensure that the quality of the contact is monitored using the NESSY system.

Note:

For other, more general information we recommend the following brochures from Erbe Elektromedizin GmbH:

- Basic Principles of Electrosurgery
- Nessy brochure
- Endoscopic Polypectomy and Mucosal Resection (EMR) with ENDO CUT Q

Literature

Akiho H, Sumida Y, Akahoshi K, Murata A, Ouchi J, Motomura Y, Toyomasu T, Kimura M, Kubokawa M, Matsumoto M, Endo S, Nakamura K. Safety advantage of endocut mode over endoscopic sphincterotomy for choledocholithiasis. *World J Gastroenterol*. 2006 Apr 7;12(13):2086-8.

Arvanitakis M, Devière J. Endoscopic Retrograde Cholangiopancreatography. *Endoscopy* 2004; 36:855-859.

ASGE guideline: the role of ERCP in disease of the biliary tract and the pancreas. *Gastrointest Endosc* 2005, 62: 1-8.

Baillie J. Complications of ERCP. ERCP and Its Applications, edited by I.M. Jacobson, Lippincott Raven Publishers, Philadelphia, 1998.

Binmoeller K, Seifert H, Gerke H, Seitz U, Portis M, Soehendra N. Papillary roof incision using the Erlangen-type precut papillotome to achieve selective bile duct cannulation. *Gastrointest Endosc* 1996; 44:689-695.

Bruins Slot W, Schoeman MN, Disario JA, Wolters F, Tytgat GN, Huibregtse K. Needle-knife sphincterotomy as a precut procedure: a retrospective evaluation of efficacy and complications. *Endoscopy* 1996; 28:334-339.

Classen M, Tytgat GNJ, Lightdale CJ. Gastroenterologische Endoskopie. Das Referenzwerk zur endoskopischen Diagnostik und Therapie. 2004, Georg Thieme Verlag Stuttgart.

Classen M, Born P. Endoskopische Papillotomie (EPT) – eine selective Literaturrecherche der beiden letzten Jahre. *Endo heute* 2003; 16:176-182.

Classen M, Born P. Endoscopic sphincterotomy. In: Tytgat GNJ, Classen M, Wayne JD, Nakazawa S, editors. Practice of therapeutic endoscopy. 3rd ed. Philadelphia: Saunders, 2000:129-46.

Costamagna G. State of the Art Review – Therapeutic biliary endoscopy. *Endoscopy* 2000; 32:209-216.

Cotton PB, Lehman G, Vennes J, Geenen JE, Russell RC, Meyers WC, et al. Endoscopic sphincterotomy complications and their management: an attempt at consensus. *Gastrointest. Endosc.* 1991; 37:383-93.

Cotton PB. Precut sphincterotomy: a risky technique for the experts only. *Gastrointest Endosc* 1989; 35:578-579.

DiSario JA, Freeman ML, Bjorkman DJ, Macmathuna P, Petersen BT, Jaffe PE, Morales TG, Hixson LJ, Sherman S, Lehman GA, Jamal MM, Al-Kawas FH, Khandelwal M, Moore JP, Derfus GA, Jamidar PA, Ramirez FC, Ryan ME, Woods KL, Carr-Locke DL, Alder SC. Endoscopic balloon dilation compared with sphincterotomy for extraction of bile duct stones. *Gastroenterology* 2004; 127:1291-1291.

Elfant AB, Bourke MJ, Alhalel R, Kortan PP, Haber GB. A prospective study of the safety of endoscopic therapy for choledocholithiasis in an outpatient population. *Am J Gastroenterol* 1996; 91:1499-1502.

Ell C, Rabenstein T, Ruppert T, Forster P, Hahn EG, Demling L. 20 years of endoscopic papillotomy: analysis of 2752 patients in Erlangen Hospital. *Dtsch Med Wochenschr* 1995; 120:163-7.

Elta GH, Barnett JL, Wille RT, Brown KA, Chey WD, Scheiman JM. Pure cut electrocautery current for sphincterotomy causes less post-procedure pancreatitis than blended current. *Gastrointest Endosc.* 1998 Feb;47(2):149-53.

Fogel E, McHenry L, Sherman S, Watkins J, Lehman G. Therapeutic Biliary Endoscopy. *Endoscopy* 2005; 37:139-145.

Fouch PG. A prospective assessment of results for needle-knife papillotomy and standard endoscopic sphincterotomy. *Gastrointest Endosc* 1995; 41:25-32.

Fuji T, Amano H, Ohmura R, Akiyama T, Aibe T, Takemoto T. Endoscopic pancreatic sphincterotomy: technique and evaluation. *Endoscopy* 1989; 21:27-30.

Fujita N, Maguchi H, Komatsu Y, Yasuda I, Hasebe O, Igarashi Y, Murakami A, Mukai H, Fujii T, Yamao K, Maeshiro K; JESED Study Group. Endoscopic sphincterotomy and endoscopic papillary balloon dilatation for bile duct stones: a prospective randomized controlled multicenter trial. *Gastrointest Endosc* 2003; 57:151-155.

- Freemann ML, Guda NM. ERCP cannulation: a review of reported techniques. *Gastrointest Endosc* 2005; 61:112-125.
- Freemann ML. Adverse outcomes of endoscopic retrograde cholangiopancreatography: avoidance and management. *Gastrointest Endosc Clin N Am* 2003; 13:775-98, xi.
- Freeman ML, Guda NM. Prevention of Post-ERCP pancreatitis: a comprehensive review. *Gastrointest Endosc* 2004; 59:845-864.
- Freeman ML. VI. Adverse events and success of ERCP – Adverse outcomes of ERCP. *Gastrointest Endosc* 2002; 56:273-282.
- Freeman ML, DiSario JA, Nelson DB, et al. Risk factors for post-ERCP pancreatitis: a prospective, multicenter study. *Gastrointest Endosc* 2001; 54:425-44.
- Freeman M. Complications of endoscopic biliary sphincterotomy: a review. *Endoscopy* 1997; 29:288-97.
- Freeman ML, Nelson DB, Sherman S, Haber GB, Herman ME, Dorsher PJ, et al. Complications of endoscopic biliary sphincterotomy. *N Engl J Med* 1996; 335:909-918.
- Goff JS. Long-term experience with the transpancreatic sphincter pre-cut approach to biliary sphincterotomy. *Gastrointest Endosc* 1999; 50:642-645.
- Gorelick A, Cannon M, Barnett J, Chey W, Scheiman J, Elta G. First cut, then blend: An electrocautery technique affecting bleeding at sphincterotomy. *Endoscopy* 2001; 33:976-980.
- Guitron A, Adalid R, Barinagarrementeria R, Gutierrez JA, Mena G, Nares J. Pre-cut sphincterotomy: efficacy and complications. *Rev Gastroenterol Mex* 1998 ;63:148-52.
- Guitron A, Adalid R. Safety and efficacy of sphincterotomy using guided and pre-cut techniques. A 5-year experience. *Rev Gastroenterol Mex* 1996; 61:342-1347.
- Häfner M and Schöfl, R. Diagnostic retrograd cholangiopancreatograph
- Hashiba K, D'Assunção MA, Armellini S, Hassegawa RT, Cappellanes CA, Moribe D. Endoscopic Suprapapillary Blunt Dissection of the Distal Common Bile Duct in Cases of Difficult Cannulation: A Pilot Series. *Endoscopy* 2004;36: 717-321.
- Hochberger J. Difficult Cannulation. In: Ginsberg G, Kochman M, Norton I, Gostout CJ, eds. *Clinical Gastrointestinal Endoscopy. Volume 1: Elsevier Saunders, USA, 2005:617-24.*
- Jacobson I. ERCP and its Applications. 1998; Lippincott – Raven Publishers, Philadelphia, New York.
- Kaffes AJ, Sriram PV, Rao GV, Santosh D, Reddy DN. Early institution of pre-cutting for difficult biliary cannulation: a prospective study comparing conventional vs. a modified technique. *Gastrointest Endosc*. 2005; 62:669-674.
- Kasmin FE, Cohen D, Batra S, Cohen SA, Siegel JH. Needle-knife sphincterotomy in a tertiary referral center: efficacy and complications. *Gastrointest Endosc* 1996; 44:48-53.
- Kohler A, Maier M, Benz C, Martin WR, Farin G, Riemann JF. A new HF current generator with automatically controlled system (Endocut mode) for endoscopic sphincterotomy: preliminary experience. *Endoscopy* 1998; 30:351-355.
- Lella F, Bagnolo, Colombo E, Umberto Bonassi, MD, et al. A simple way of avoiding post-ERCP pancreatitis. *Gastrointest Endosc*. 2004; 59:830-834.
- Levy MJ, Geenen JE. Endoscopic management of benign pancreatic diseases. In: Tytgat GN, Classen M, Waze JD, Nakazawa J, editors. *Practice of therapeutic endoscopy*. 2nd ed. London: Saunders, 2000:177-197.
- Macintosh DG, Love J, Abraham NS. Endoscopic sphincterotomy by using pure-cut electrosurgical current and the risk of post-ERCP pancreatitis: a prospective randomized trial. *Gastrointest. Endosc*. 2004; 60:551-556.
- Martin DF, England R, Martin O. The safety sphincterotome: the device, the technique, and preliminary results. *Endoscopy* 1998; 30:375-378.
- Masci E, Toti G, Mariani A, et al. Complications of diagnostic and therapeutic ERCP: A prospective multicenter study. *Am J Gastroenterol* 2001; 96:417-423.
- Maguchi H, Takahashi K, Kanatuma A. Pancreatic and bile duct stricture – Endoscopic management of biliary and pancreatic ducts strictures. *Digest Endosc* 2004; 16 (Suppl.):34-38.
- Maydeo A, D. Borkar D. Techniques of selective cannulation and sphincterotomy. *Endoscopy* 2003; 35:19-23.
- Mavrogiannis C, Liatsos C, Romanos A, Petoumenos C, Nakos A, Karvountzis G. Needle-knife fistulotomy versus needle-knife precut papillotomy for the treatment of common bile duct stones. *Gastrointest Endosc* 1999; 50:334-9.
- Mergener K, Kozarek RA. Therapeutic pancreatic endoscopy. *Endoscopy* 2005; 37:201-207.
- Neuhaus H. Therapeutic pancreatic endoscopy. *Endoscopy* 2004; 36: 8-16.
- Norton ID, Petersen BT, Bosco J, Nelson DB, Meier PB, Baron TH, Lange SM, Gostout CJ, Loeb DS, Levy MJ, Wiersema MJ, Pochron N. A randomized trial of endoscopic biliary sphincterotomy using pure-cut versus combined cut and coagulation waveforms. *Clin Gastroenterol Hepatol*. 2005; 3:1029-1033.
- Park SH, Kim HJ, Park DH, Kim JH, Lee JK, Lee SH, Chung IK, Kim HS, Kim SJ. Pre-cut papillotomy with a new papillotome. *Gastrointest Endosc* 2005; 62: 588-591.
- Kaloo AN, Thuluvath PJ, Pasricha PJ. Treatment of high-risk patients with symptomatic cholelithiasis by endoscopic gallbladder stenting *Gastrointest Endosc*. 1994 Sep-Oct;40(5):608-10.
- Perini RF, Sadurski R, Cotton PB, Patel RS, Hawes RH, Cunningham JT. Post-sphincterotomy bleeding after the introduction of microprocessor-controlled electrosurgery: does the new technology make the difference? *Gastrointest Endosc* 2005; 61:53-57.
- Rabenstein T, Schneider HT, Nicklas M, Ruppert T, Katalinic A, Hahn EG, et al. Impact of skill and experience of the endoscopist on the outcome of endoscopic sphincterotomy techniques. *Gastrointest Endosc* 1999; 50:628-36.
- Rabenstein T, Ruppert T, Schneider HT, Hahn EG, Ell C. Benefits and risks of needle-knife papillotomy. *Gastrointest Endosc* 1997; 46:207-11.
- Riemann JF. [Endoscopic treatment of gallstones: new technics] *Z Gesamte Inn Med*. 1989 Oct 15;44(20):605-9.
- Rollhauser C, Johnson M, Al-Kawas FH. Needle-knife papillotomy: a helpful and safe adjunct to endoscopic retrograde cholangiopancreatography in a selected population. *Endoscopy* 1998; 30:691-696.
- Sherman S, Ruffolo T, Hawes RH, Lehman GA. Complications of endoscopic sphincterotomy. *Gastroenterology* 1991; 101: 1068-1075.
- Silverstein F.E., Tytgat G.N.J. *Praxis der Gastroenterologischen Endoskopie; Atlas und Lehrbuch*, 1999; Georg Thieme Verlag, Stuttgart
- Soehendra N, Binmoeller KF, Seifert H, Schreiber HM. *Therapeutic Endoscopy. Color Atlas of Operative Techniques for the Gastrointestinal Tract*. 2005, Georg Thieme Verlag, Stuttgart.
- Sriram PV, Rao GV, Nageshwar Reddy D. The precut: when, where and how? A review. *Endoscopy* 2003; 35: 24-30.
- Stefanidis G, Karamanolis G, Viazis N, Sgouros S, Papadopoulou E, Ntatsakis K, Mantides A, Nastos H. A comparative study of postendoscopic sphincterotomy complications with various types of electrosurgical current in patients with choledocholithiasis. *Gastrointest Endosc* 2003; 57: 192-197.
- Sugiyama M, Suzuki Y, Abe N, Masaki T, Mori T, Atomi Y. Pancreas and Biliary – Endoscopic retreatment of recurrent choledocholithiasis after sphincterotomy. *Gut* 2004; 53:1856-1859.
- Tang SJ, Haber GB, Kortan P, Zanati S, Cirocco M, Ennis M, Elfant A, Scheider T, Ter H, J. Dorais J. Precut papillotomy versus persistence in difficult biliary cannulation: A prospective randomized trial. *Endoscopy* 2005; 37:58-65.



Erbe Elektromedizin GmbH
Waldhoernlestrasse 17
72072 Tuebingen
Germany

Phone +49 7071 755-0
Fax +49 7071 755-179
info@erbe-med.com
erbe-med.com